

MONOPOLAR CAPACITIVE / RESISTIVE RADIOFREQUENCY AT 448 kHz IN THE TREATMENT OF DISORDERS OF THE SUPERFICIAL FLEXOR TENDON IN HORSES. CLINICAL CASE

CAMPOS, MJ^{1,2}, AGÜERA E.I.¹, REQUENA F.¹

¹Department of Cellular Biology, Physiology and Immunology. University of Córdoba ²Doctoral students researching "Use of capacitive/resistive monopolar radiofrequency at 448 kHz in equine tendon disorders"



UNIVERSIDAD DE CÓRDOBA

ANIMAL PHYSIOLOGY SECTION

Department of Cellular Biology, Physiology and Immunology
Edificio Darwin, 2ª planta. Campus de Rabanales. 14014 Córdoba. Spain.

INTRODUCTION

Tendon disorders are highly prevalent in competition horses. They entail a physical and functional limitation in the activity of the animal and require specific treatment.

The current therapeutic approach resorts to basically conservative, regenerative and/or surgical treatments depending on the origin and severity of the disorder. The objective of the therapy is to accelerate recovery and to enable the horse to return to its usual activity quickly.

It has been described that radiofrequency currents at 448 kHz have the ability to promote the proliferation of stem cells, with activity that is key to tissue regeneration (Hernández-Bule et al, 2014) which jointly with analgesic activity (Labanda 2009) justify the interest in its application in the treatment of tendon pathologies in horses.

The effect is achieved through a triple mechanism of action:

- *Biostimulation*. The subthermal effect induces movement in the extracellular matrix, facilitating cell nutrition and improving cell metabolism.
- *Vascularisation*. It improves microcirculation and vasodilatation, favouring tissue drainage and improved cell oxygenation.
- *Metabolic hyperactivation*. The increase in cell metabolism results in better, faster regeneration. The tissue repair produces better quality tissue, which prevents the recurrence of the injury.

OBJECTIVES

The objective of this study was to evaluate the efficacy of monopolar capacitive resistive radiofrequency (MCRRF) at 448 kHz in the treatment of a disorder of the superficial flexor tendon (SFT) of a horse, and its safety and innocuousness.

MATERIAL AND METHODS

A 7-year-old Spanish crossbreed dressage horse was brought to the clinical hospital of the University of Córdoba for evaluation and treatment. The animal presented bilateral tendinopathy of the superficial flexor tendon, chronic in the front left limb (FLL) and acute in the front right limb (FRL).

Upon clinical examination, the horse did not present lameness, but suffered severe pain upon palpation of the body of the SFT of the right foot. In both feet, the increased size of the SFT was noted, both visually and through palpation.

Ultrasound scanning was used for the diagnosis and characterisation of the tendinopathy: Figs. 1-2. The infiltration technique is documented in Figs. 3-4.

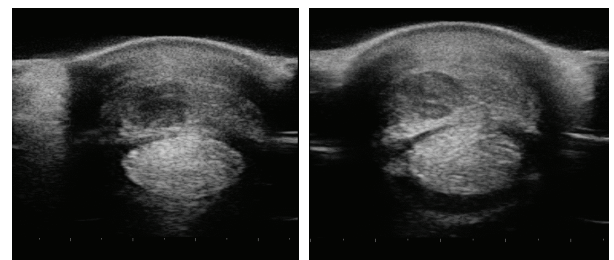


Figure 1. Ultrasound scans of the FRL (acute lesion)

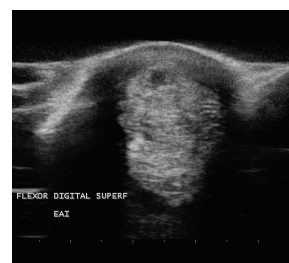


Figure 2. Ultrasound scans of the FLL (chronic lesion)

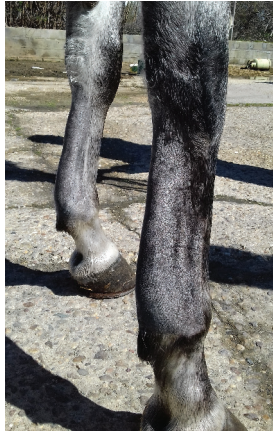

Figure 3. Front limbs



Figure 4. Intralesional infiltration of the superficial flexor tendon of the FRL with platelet-rich plasma



Figure 5. Front limbs after the first INDIBA® treatment

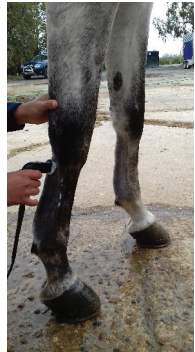

Figure 6. Application of INDIBA®

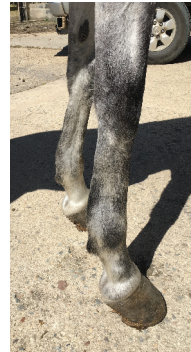

Figure 7. Front limbs after 8 sessions of INDIBA®

Therapeutic Approach

An MCRRF at 448 kHz INDIBA® Model VET905 was used (INDIBA® Animal Health, INDIBA S.A., Barcelona, Spain). This unit emits in continuous mode; the treatment was applied using a combination of two different types of electrodes: capacitive (CAP) and resistive (RES). The treatment protocol was established according to the characteristics of the lesion and the degree of impact of the injury. Eight sessions were applied at intervals of 2 days between each session.

In the FRL (acute phase tendinopathy) an intralesional infiltration with platelet-rich plasma (PRP) was carried out and MCRRF was applied immediately. The starting powers applied (expressed in % of the maximum value) were low and gradually increased over time. Sessions had a total duration of 25 minutes per session. An acute lesion is characterised by inflammation and increased temperature, so the treatment of choice is work under subthermal conditions, which can promote the drainage of the tissue and reduce inflammation. In successive applications the power was increased gradually.

In the FLL (chronic phase tendinopathy) only MCRRF was applied, at a higher power with the objective of inducing a controlled exacerbation of the injury, able to break the fibrosis that had already formed and simultaneously induce the local activation of endogenous growth factors.

Sessions duration was 15 minutes during the first three sessions, and then 25 minutes per session until completing the 8-session protocol.

RESULTS AND DISCUSSION

Notable anti-inflammatory effect was verified after the treatment, visible to the naked eye, from the first treatment. The effect was most noticeable from the third application and until the resolution of the treatment.

In the post treatment ultrasound control (a month and a half after the baseline ultrasound scans and the first treatment), regeneration of the broken tendon fibres was verified. They were shown to be more organised and consistent.

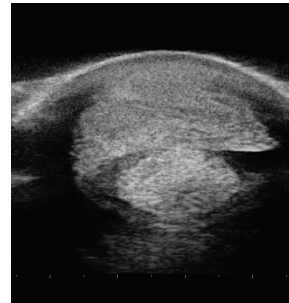


Figure 8. Ultrasound image of the front left limb after 8 sessions of INDIBA®

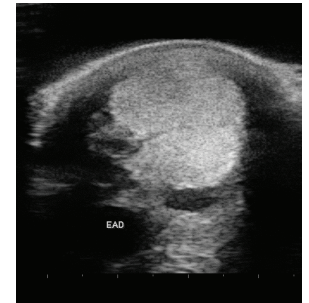


Figure 9. Ultrasound image of the front right limb after 8 sessions of INDIBA®

The treatment was well tolerated by the animal. The results of this control study would support a reproduction of the results recorded in human medicine, especially in the field of sports medicine and rehabilitation (Sanguedolce et al 2009, Paciulli 2013, Vall et al 2011).

The use of MCRRF at 448 kHz may be a useful tool in the therapeutic options available in veterinary medicine for rehabilitation.

BIBLIOGRAPHY

- Hernández-Bule ML, Paino CL, Trillo MA, Ubeda A. Electric Stimulation at 448 Khz Promotes Proliferation of Human Mesenchymal Stem Cells. *Cell Physiol Biochem.* 2014;34(5): 1741-55.
- Labanda MJ. Resultados del uso de corrientes de alta frecuencia en el dolor crónico provocado por tendinopatía rotuliana 2009 [Available from: <https://www.efisioterapia.net/articulos/resultados-del-uso-corrientes-alta-frecuencia-el-dolor-cronico-provocado-tendinopatia-rotu>]
- Sanguedolce G, Cataldo C. V., P., Mauro, L. (2009). Tecarterapia nelle tendinopatie della cuffia dei rotatori. SIMFER 37° Congresso Nazionale Campobasso
- Paciulli, C. M. (2013). Tecarterapia en epicondilitis, Universidad FASTA
- Vall, J., S. Sendrós, F. Sust, X. Linde and L. Til (2011). Radiofrecuencia monopolar capacitiva / resistiva 448 kHz (INDIBA®), como Terapia de Rehabilitación en Medicina Deportiva. XXIII Jornadas de la Asociación Española de Médicos de Baloncesto. Bilbao, Universitat Pompeu Fabra